



Ocular Manifestation of Ataxia with Isolated Vitamin E Deficiency

Abdi Rhizlane^{1*}, Chariba Siham¹, Asmae Maadan¹ and Rachid Sekhsoukh¹

¹CHU MED VI, Oujda Maroc, Morocco.

Authors' contributions

This work was carried out in collaboration among all authors. Author AR designed the study, performed the statistical analysis, wrote the protocol and wrote the first draft of the manuscript. Author AR managed the literature searches. All authors read and approved the final manuscript.

Article Information

Editor(s):

(1) Dr. Panagiotis Tsikripis, University of Athens, Greece.

Reviewers:

(1) Chikezie Grand Ihesiulor, Abia State University, Nigeria.

(2) Catherine Ukponmwan, University of Benin, Nigeria.

(3) Shubha Ghonsikar Jhavar, Government Medical College, Aurangabad, India.

Complete Peer review History: <http://www.sdiarticle4.com/review-history/56281>

Case Study

Received 15 February 2020

Accepted 22 April 2020

Published 27 April 2020

ABSTRACT

Ataxia with Isolated Vitamin E deficiency (AVED) is an autosomal recessive neurodegenerative disease. The present study reports the case of a 37-year-old patient. Followed since 12 years for Ataxia with Isolated Vitamin E Deficiency, supplemented with vitamin E, stopped for 4 years ago. The ophthalmological examination found a vertical nystagmus, corrected visual acuity at 8/10 to the right and left. Normal anterior segment were seen in both eyes. AVED is clinically characterized by progressive cerebellar ataxia, dysarthria, loss of proprioception and sense of vibration, and the absence of tendon and extensor plantar reflex. Vitamin E prevents lipid oxidation in membranes, is normally present in high concentrations in the photoreceptors of the outer segments in the retina. These results identify abnormalities of the a-TTP gene as a cause of retinitis pigmentosa. Present study emphasizes the importance of serum vitamin E screening in patients with spinocerebellar degeneration resembling Friedreich's ataxia, particularly if the clinical features include retinitis pigmentosa, since this neurological disorder can be arrested by appropriate supplementation with vitamin E.

Keywords: *Vitamin E; cerebellar ataxia; reflex action; retinitis pigmentosa.*

*Corresponding author: E-mail: rhizlane_a@hotmail.com;

1. INTRODUCTION

Ataxia with Isolated Vitamin E deficiency (AVED) is an autosomal recessive neurodegenerative disease. Clinical features include cerebellar ataxia, dysarthria, lower limb areflexia, a sense of vibration and bilateral extensor plantar reflexes [1].

AVED is caused by mutations in the α -tocopherol transfer protein gene (TTPA) located on chromosome 8q13 (GeneBank number NM_000370).

Some AVED patients present with retinitis pigmentosa due to a loss of antioxidant effects of vitamin E.

2. CASE REPORT

We report the case of a 37-year-old patient. Followed since 12 years for Ataxia with Isolated

Vitamin E Deficiency, Supplemented with vitamin E, stopped for 4 years ago.

On physical examination, she exhibited ataxia, dysarthria. The ophthalmological examination found a vertical nystagmus, corrected visual acuity at 8/10 to the right and left eye. Normal anterior segment in both eyes.

Fundus showed the typical changes of retinitis pigmentosa (Fig. 1).

Macular OCT showed slight macular atrophy of the left eye (Fig. 2).

Laboratory data revealed a low serum vitamin E concentration. Cerebral magnetic resonance imaging (MRI) showed Vermian and cerebellar atrophy (Fig. 3).

There was no abnormality on electrocardiography (ECG).

OS(L)

Capture Date : 18/10/2019

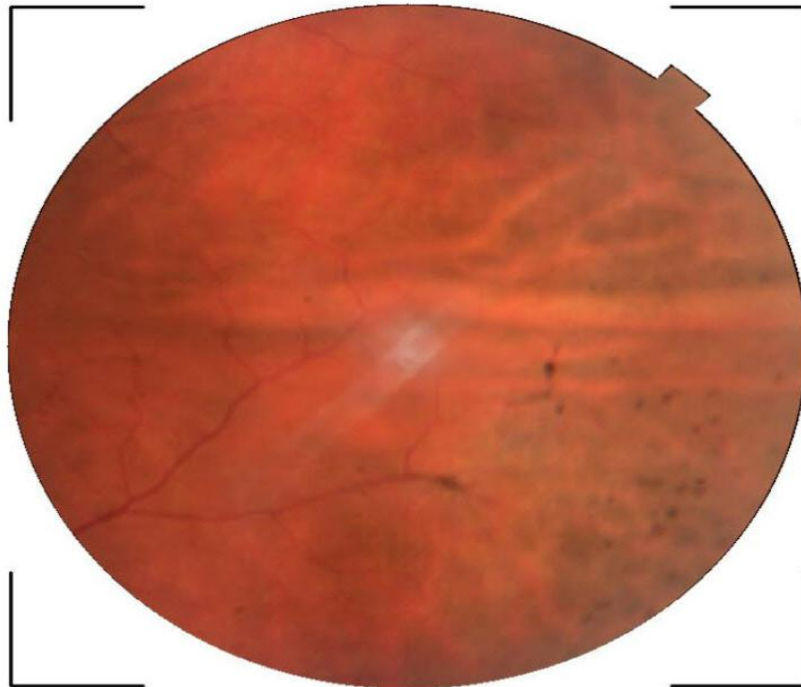


Fig. 1. Photograph of the Retina of patient showing black

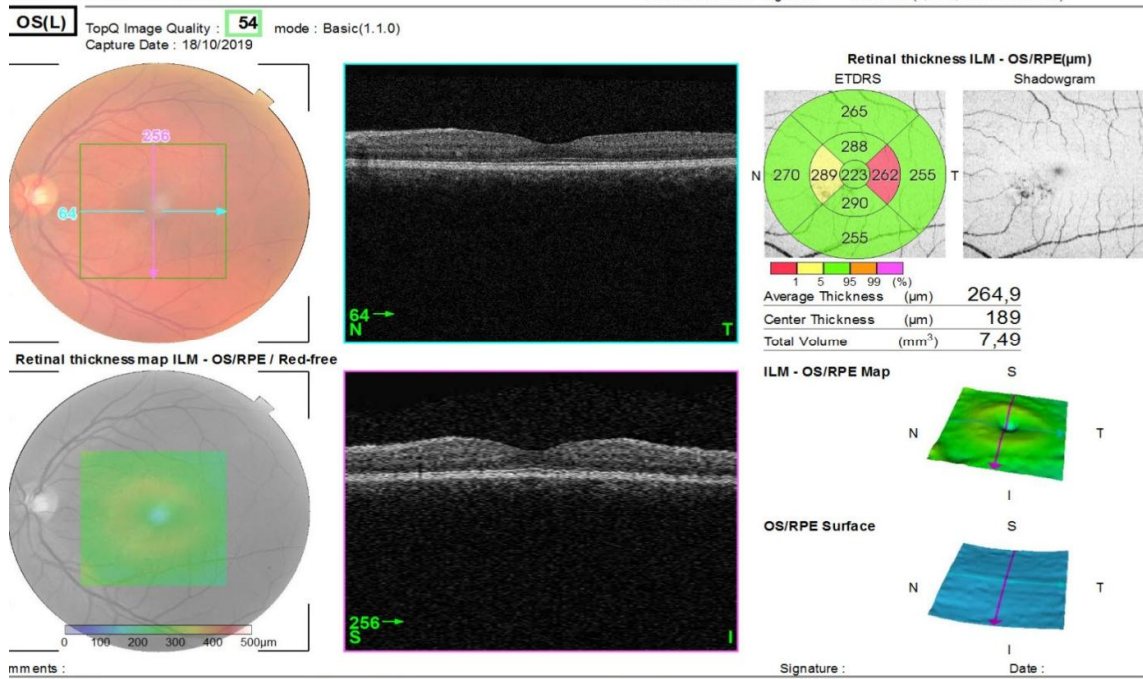


Fig. 2. Macular OCT showing slight macular atrophy of the left eye

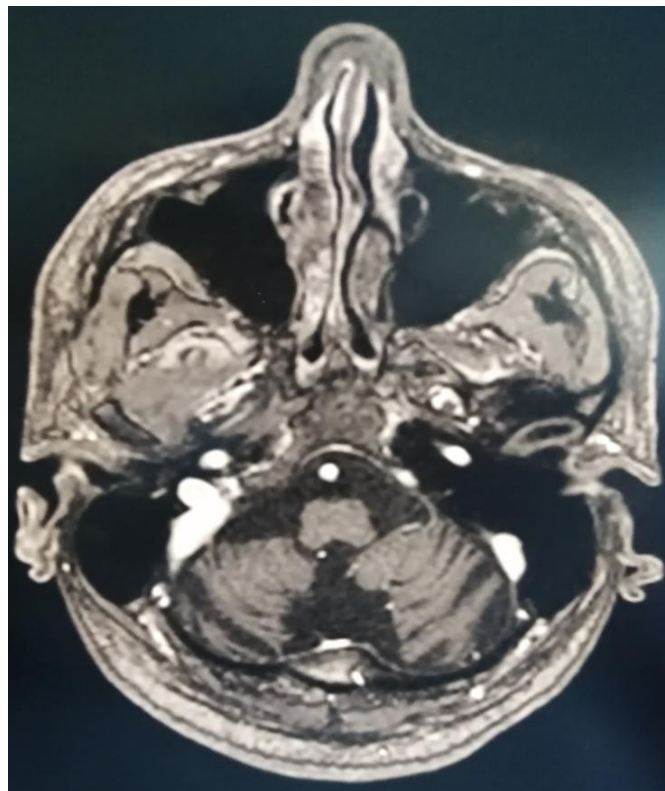


Fig. 3. Cerebral Magnetic Resonance Imaging (MRI) in axial section showing vermial and cerebellar atrophy

3. DISCUSSION

AVED is clinically characterized by progressive cerebellar ataxia, dysarthria, loss of proprioception and sense of vibration, and the absence of tendon and extensor plantar reflexes. AVED is caused by mutations in the α -tocopherol transfer protein gene (TTPA) located on chromosome 8q13 (GeneBank number NM_000370) [1].

Tea α -tocopherol transfer protein (α -TTP) is a liver protein vitamin E (α -tocopherol) to a very-low-density lipoprotein (VLDL). VLDLs circulate throughout the body and regulate plasma vitamin E levels [2].

AVED patients have very low vitamin serum E levels because has mutation in α -TTP inhibits its ability to bind VLDL [3].

Vitamin E is an antioxidant that is incorporated into VLDL and prevents lipid oxidation. Vitamin E deficiency results in compromised scavenging functions and plays a major role in the neurodegeneration observed in AVED [4].

Vitamin E, which prevents lipid oxidation in membranes, is normally present in high concentrations in the photoreceptors of the outer segments in the retina. Because the outer-segment membranes contain an unusually high percentage of polyunsaturated fatty acids, they are very susceptible to damage by oxidation. Retinal changes similar to those of retinitis pigmentosa have been reported in patients with vitamin E deficiency due to fat malabsorption and in experiments in animals.

It is not surprising, therefore, that our patients with severe long-term vitamin E deficiency had retinitis pigmentosa [5].

Electroretinogram and fluorescein angiography investigations show the retina to be affected in asymptomatic patients [6].

A few histologic examinations show a depletion of the photoreceptors and an accumulation of lipofuscin (a brownish pigment left over from the breakdown and absorption of damaged cells) in the retina [7].

These results identify abnormalities of the α -TTP gene as a cause of retinitis pigmentosa. In patients with these mutations vitamin E therapy

appears to stop or slow the progression of retinitis pigmentosa [8].

4. CONCLUSION

Our report emphasizes the importance of serum vitamin E screening in patients with spinocerebellar degeneration resembling Friedreich's ataxia, particularly if the clinical features include retinitis pigmentosa, since this neurological disorder can be arrested by appropriate supplementation with vitamin E.

CONSENT

As per international standard or university standard, patient's written consent has been collected and preserved by the author(s).

ETHICAL APPROVAL

As per international standard or university standard written ethical approval has been collected and preserved by the author(s).

COMPETING INTERESTS

Authors have declared that no competing interests exist.

REFERENCES

1. Anheim M, Fleury M, Monga B, et al. Epidemiological, clinical, paraclinical and molecular study of a cohort of 102 patients affected with autosomal recessive progressive cerebellar ataxia from Alsace, Eastern France: implications for clinical management. *Neurogenetics*. 2010;11: 1–12.
2. Kim HS, Arai H, Arita M, Sato Y, Ogihara T, Tamai H, Inoue K, Mino M. *J Nutr Sci Vitaminol*. 1996;42:11–18.
3. Alpha-Tocopherol Transfer Protein (α -TTP): Insights from Alpha-Tocopherol Transfer Protein Knockout Mice, *Nutr Res Pract*. 2007;1(4):247–253.
4. Maret G. Traber¹, Jeffrey Atkinson², Vitamin E. Antioxidant and Nothing More, *Free Radic Biol Med*; 2007.
5. Robison WG, Kuwabara T, Bieri JG. The roles of vitamin E and unsaturated fatty acids in the visual process. *Retina*. 1982;2(4):263-81.
6. Berriot-Varoqueaux N, Aggerbeck LP, Samson-Bouma ME, Wetterau JR.

- The role of the microsomal triglyceride transfer protein in abetalipoproteinemia. *Annu Rev Nutr.* 2000;20:663-97.
7. Chowers I, Banin E, Merin S, Cooper M, Granot E. Long-term assessment of combined vitamin A and E treatment for the prevention of retinal degeneration in abetalipoproteinaemia and hypobetalipoproteinaemia patients. *Eye.* 2001;15(Pt 4):525-530.
8. Daiger SP, Sullivan LS, Bowne SJ. Genes and mutations causing retinitis pigmentosa, *Clin Genet.* 2013;84(2).

© 2020 Rhizlane et al.; This is an Open Access article distributed under the terms of the Creative Commons Attribution License (<http://creativecommons.org/licenses/by/4.0>), which permits unrestricted use, distribution, and reproduction in any medium, provided the original work is properly cited.

Peer-review history:
The peer review history for this paper can be accessed here:
<http://www.sdiarticle4.com/review-history/56281>