



# **Management of Medication-related Osteonecrosis of Posterior Maxilla with Buccal Fat Pad Flap: Case Report**

**Kagan Deniz<sup>1\*</sup> and Firdevs Senel<sup>2</sup>**

<sup>1</sup>*Department of Oral and Maxillofacial Surgery, School of Dentistry, Baskent University, Turkey.*

<sup>2</sup>*Department of Oral and Maxillofacial Surgery, School of Dentistry, Beykent University, Turkey.*

## **Authors' contributions**

*This work was carried out in collaboration between both authors. Both authors read and approved the final manuscript.*

## **Article Information**

### Editor(s):

(1) Dr. M. Jaya Nagendra Krishna, Kamineni Institute of Dental Sciences, India.

### Reviewers:

(1) Angela Tempesta, University of Bari, Italy.

(2) Herold Manfred, Medical University of Innsbruck, Austria.

Complete Peer review History: <http://www.sdiarticle4.com/review-history/54725>

**Case Study**

**Received 12 December 2019**

**Accepted 20 February 2020**

**Published 03 March 2020**

## **ABSTRACT**

Bisphosphonates are one of the most commonly prescribed drugs in bone-associated diseases. Medication-related osteonecrosis of the jaws (MRONJ) is a new term and the common side effect of long term bisphosphonate therapy; characterized by the presence of exposed necrotic bone and non-healing mucosa. Although there has been an increasing number of MRONJ cases; its management is still a challenge for clinicians. In this case report, the management of MRONJ with buccal fat pad flap in an osteoporotic patient is described.

*Keywords: Medication; osteonecrosis; posterior maxilla; bisphosphonate therapy.*

## **1. INTRODUCTION**

Anti-resorptive and anti-angiogenic drugs, such as bisphosphonates, denosumab, bevacizumab, infliximab play an important role in the treatment

of metastatic bone diseases, paget disease, fibrous dysplasia, multiple myeloma, Crohn's disease, rheumatoid arthritis and osteoporosis, although they may also be responsible for the occurrence of medication-related osteonecrosis

*\*Corresponding author: Email: drkagandeniz@gmail.com;*

of the jaw (MRONJ) [1-3]. MRONJ has been defined by the American Association of Oral and Maxillofacial Surgeons (AAOMS) as the presence of exposed necrotic bone or bone that can be probed through an intra-oral or extra-oral fistula in the maxillofacial region, which has persisted for longer than 8 weeks, occurring in patients undergoing treatment with anti-resorptive or anti-angiogenic agents with no history of radiation therapy or obvious metastatic disease to the jaws [1].

Although there have been an increasing number of MRONJ cases since its first description in 2003 by Marx, acknowledgement regarding the management of this condition is still a challenge and dilemma [3]. Previous reports were noted that surgical management of this condition would lead to further osteonecrosis and so the treatment was limited to drug holiday, chlorhexidine mouth rinses, systemic antibiotics and protection the area from local trauma and there is no consensus regarding a non-surgical versus a surgical approach [4-7].

As, one of the opinions about MRONJ generation is based on impaired soft tissue healing reconstructing the site with well-vascularized tissues should be considered to obtain predictable healing when surgical treatment is inevitable [8].

Buccal fat pad flap is a well-described technique and it has proved of value for the treatment of oro-antral communications [9,10]. Although there have been various indications for buccal fat pad flap implementation in oral and maxillofacial surgery, we presented its use in MRONJ management in stage II case with reference to AAOMS position paper [11].

In this case report, the management of MRONJ occurred secondary to tooth extraction in an osteoporotic patient is described.

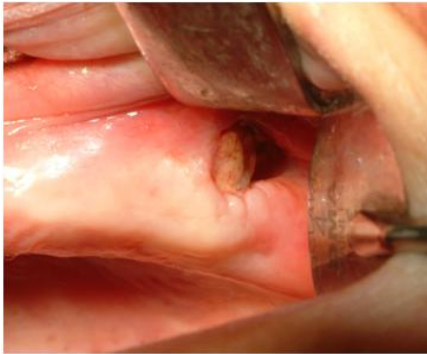## 2. CASE PRESENTATION

64 year-old maxillary edentulous woman was referred to the clinic for removal of maxillary impacted third molar. The past medical history was positive for diabetes mellitus, rheumatoid arthritis and hyperthyroidism. Extraction was performed under local anesthesia and mucosa was subsequently sutured primarily. 10 days after the extraction, patient call us for persistent

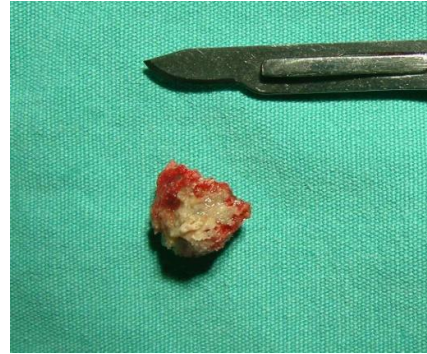pain and mucosal swelling of the operated area. In oral examination, the mucosa was erythematous and tender to palpation. Curettage was done and oral antibiotics (amoxicillin 500 mg, 3 times daily) and mouth rinse (0.12% chlorhexidine) was prescribed.

However, 2 months later patient-reported same symptoms as initial. Panoramic radiography showed non-healed bone in the third molar socket. Local debridement of the area and primary closure of the mucosa was performed. In following controls, due to recurrent mucosal opening, it was decided to let the wound, take care of itself and irrigated with rifamycin (Rifocin 125 mg/1,5 ml flacon) regularly. At the end of the 1 month, lesion restricted itself and typical stage II MRONJ appearance characterized with exposed necrotic bone surrounded by inflamed-erythematous oral mucosa was arised (Fig. 1).

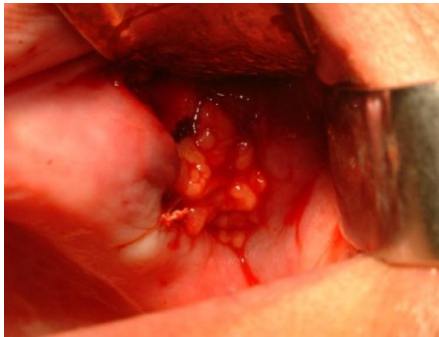Due to typical MRONJ appearance, whether the patient had ever receive bisphosphonate therapy was questioned it was revealed that, she had been diagnosed with osteoporosis and has received oral risedronate sodium for 10 years. Therefore, bisphosphonate therapy was ceased and the patient was scheduled to perform sequestrectomy. Under local anesthesia sequester 20 x 10 x 10 mm in size was removed (Fig. 2). However oral mucosa was not enough for primary closure without tension. Buccal fat pad flap which is commonly used for closure of oro-antral communications is considered for soft tissue reconstruction. After horizontal incision from the zygomatic buttress to the posterior maxilla, blunt dissection through the m. buccinator and its fascia were performed. Buccal fat pad was herniated into the mouth, and buccal extension of this tissue was pulled over the defect and sutured to deepithelialized mucosal margins (Fig. 3). Combined antibiotics; composed of amoxicillin+clavulanic acid (Augmentine 625 mg) and metronidazole (Flagyl 500 mg), paracetamol (Parol 500 mg) and chlorhexidine mouth rinse were prescribed and the patient was instructed for regular controls. The removed sequester was examined histopathologically and leukocyte-rich mixed inflammatory cells, among the necrotic bone trabecules with empty lacunes were detected (Figs. 4, 5). Fat tissue surface was epithelialized and the defect was completely covered with normal mucosa. There was no recurrence in the follow-up period of 7 months (Fig. 6).



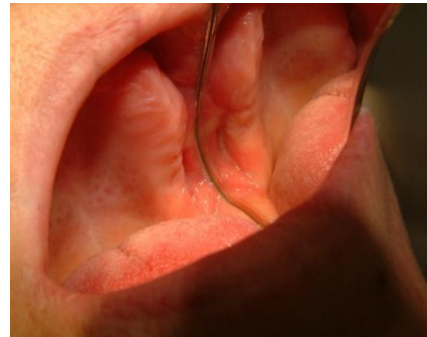**Fig. 1. Clinical view of the exposed necrotic bone and surrounding soft tissue**



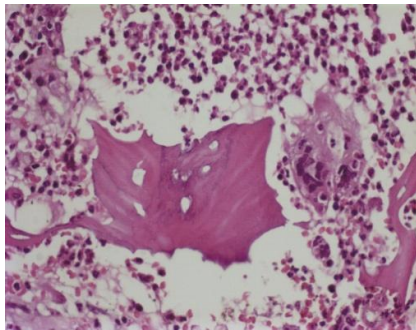
**Fig. 2. View of removed sequestrum**



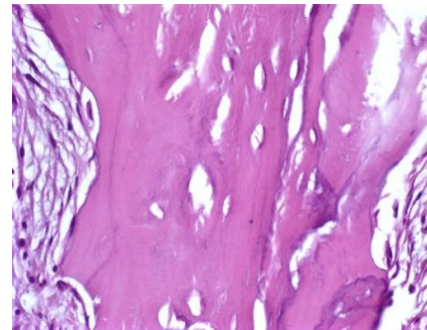
**Fig. 3. Intraoperative photograph illustrating the defect closure with pedicled buccal fat pad flap**



**Fig. 4. Leukocyte-rich inflammatory infiltration with acellular lacunae (H&E, x400)**



**Fig. 5. Acellular lacunae of necrotic trabeculae (H&E, x400)**



**Fig. 6. Intraoral view of the area 7 months after the surgery**

### 3. DISCUSSION

MRONJ begins mostly in patients under IV bisphosphonate therapy for malignancies. However, reports of MRONJ occurred in long-term oral bisphosphonate users have also been published. Many authors have reported that extraction of the teeth was a trigger factor in the occurrence of MRONJ [12].

Management of MRONJ is still complicated. Nowadays, management strategy is non-surgical treatment; in which treatment consists of; maintenance of good oral hygiene, antibiotics, analgesics, chlorhexidine mouth rinse use or surgical treatment [11]. However, even after this protocol, so many patients still present with, or progress to, severe bone necrosis [12]. In our patient, medical therapy and superficial

debridement was failed to alleviate the symptoms.

Primary closure of surrounding soft tissue is very important for healing of necrotic bone. Bisphosphonates cause, oral soft tissue toxicity and healing damage with long term usage. For the management of exposed necrotic bone, additional free soft tissue flaps should be considered [8].

Reconstruction of the palate, buccal mucosa, closure of oro-nasal fistulas and coverage of the surface of the bone grafts, and reconstruction after post-traumatic defects in the maxillary area with a well-vascularized buccal fat pad has been documented [9,10]. Anatomically, its blood supply is provided by the maxillary artery, superficial temporal artery and facial artery [13].

The buccal fat pad flap may be considered as a safe method for soft tissue closure [9,10]. Pedicled buccal fat pad flap quick epithelialization of the uncovered fat is a characteristic feature and its histologically proven. The stratum above the originally uncovered buccal fat pad consists of stratified squamous epithelium migrating from the adjacent mucosal regions [14,15].

Main drawback of our treatment is that it can only be used posterior maxillary bone necrosis area and limitations exist concerning the size of the necrotic bone area to be closed. Although the size of the defects has been up to 60 x 50 x 30 mm in literature [15,16], successful closure was obtained mostly in small defects and oro-antral communications.

#### 4. CONCLUSION

Based on the outcome of the presented case, pedicled buccal fat pad flap may be considered as an alternative and safe procedure in MRONJ management in posterior maxilla when additional soft tissue is required with keeping in mind its recommendations and limitations.

#### CONSENT

As per international standard, patient's written consent has been collected and preserved by the author(s).

#### ETHICAL APPROVAL

As per international standard, written ethical approval has been collected and preserved by the author(s).

#### COMPETING INTERESTS

Authors have declared that no competing interests exist.

#### REFERENCES

1. Ruggiero SL, Dodson TB, Fantasia J, Goodday R, Aghaloo T, Mehrotra B. American association of oral and maxillofacial surgeons. American Association of Oral and Maxillofacial Surgeons position paper on medication-related osteonecrosis of the jaw – 2014 Update. *Journal of Oral and Maxillofacial Surgery*. 2014;72(10):1938–1956. Available: <https://doi.org/10.1016/j.joms.2014.04.031>
2. Favia G, Tempesta A, Limongelli L, Crincoli V, Iannone F, Lapadula G, Maiorano E. A case of osteonecrosis of the jaw in a patient with Crohn's disease treated with infliximab. *Am J Case Rep*. 2017;18:1351-1356.
3. Marx RE. Pamidronate (aredia) and zoledronate (Zometa) induced avascular necrosis of the jaws: A growing epidemic. *J Oral Maxillofac Surg*. 2003;61:1115.
4. Pazianas M, Miller P, Blumentals WA, Bernal M, Kothawala P. A review of the literature on osteonecrosis of the jaw in patient with osteoporosis treated with oral bisphosphonates: Prevalance, risk factors, and clinical characteristics. *Clin Ther*. 2007;29:1548-1558.
5. Rizzoli R, Burlet N, Cahall D, et al. Osteonecrosis of the jaw and bisphosphonate treatment for osteoporosis. *Bone*. 2008;42:841-847.
6. Ruggiero SL, Dodson TB, Assael LA, Landesberg R, Marx RE, Mehrotra B. American association of oral and maxillofacial surgeons position paper on bisphosphonate-related osteonecrosis of the jaws-2009 update. *J Oral Maxillofac Surg*. 2009;67:2-12.
7. Hayashida S, Soutome S, Yanamoto S, Fujita S, Hasegawa T, Komori T, Umeda M. Evaluation of the treatment strategies for Medication-Related Osteonecrosis of the Jaws (MRONJ) and the factors affecting treatment outcome: A multicenter retrospective study with propensity score matching analysis. *Journal of Bone and Mineral Research*, Epublication ahead of Print; 2017. Available: <https://doi.org/10.1002/jbmr.3191>

8. Ian R. Reid, Mark J. Bolland, Andrew B. Grey. Is bisphosphonate-associated osteonecrosis of the jaw caused soft tissue by toxicity? *Bone*. 2007;41:318–320.
9. Hanazawa Y, Itoh K, Mabashi T, et al. Closure of oroantral communications using a pedicled buccal fat pad graft. *J Oral Maxillofac Surg*. 1995;53:771.
10. Dean A, Alamillos F, Garcia-LoPez A, et al. The buccal fat pad flap in oral reconstruction. *Head Neck*. 2001;23:383.
11. Advisory task force on bisphosphonate-related osteonecrosis of the jaws. AAMOS: American Association of Oral and Maxillofacial Surgeons position paper on bisphosphonate-related osteonecrosis of the jaws. *J Oral Maxillofac Surg*. 2007;65: 369.
12. Pazianas M, Miller P, Blumentals WA, Bernal M, Kothawala P. A review of the literature on osteonecrosis of the jaw in patient with osteoporosis treated with oral bisphosphonates: Prevalance, risk factors, and clinical characteristics. *Clin Ther*. 2007;29:1548-1558.
13. Zhang MH, Yan Y, Ming Q, et al. Anatomical structure of the buccal fat pad and its clinical adaptations. *Plast Reconstr Surg*. 2002;109:2509.
14. Baumann A, Ewers E. Application of the buccal fat pad in oral reconstruction. *J Oral Maxillofac Surg*. 2000;58: 389.
15. Jackson IT. Anatomy of the buccal fat pad and its clinical significance. *Plast Reconstr Surg*. 1999;103:2059.
16. Fujimura N, Nagura H, Enomoto S. Grafting of the buccal fat pad into palatal defects. *J Craniomaxillofacial Surg*. 1990;18:219.

© 2020 Deniz and Senel; This is an Open Access article distributed under the terms of the Creative Commons Attribution License (<http://creativecommons.org/licenses/by/4.0>), which permits unrestricted use, distribution, and reproduction in any medium, provided the original work is properly cited.

*Peer-review history:*

*The peer review history for this paper can be accessed here:  
<http://www.sdiarticle4.com/review-history/54725>*